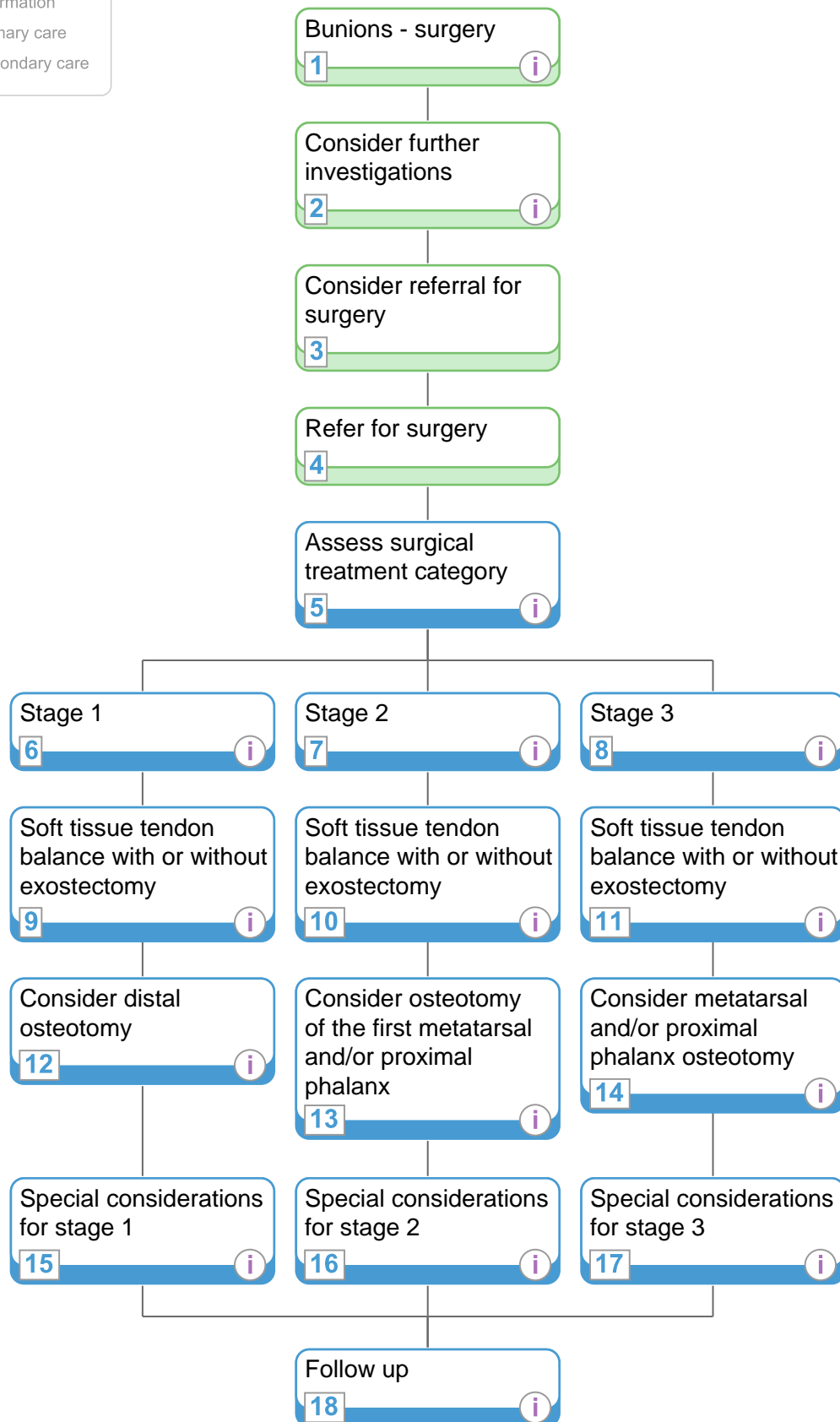


<http://healthguides.mapofmedicine.com/choices/map/bunions3.html>

i Information  
 Primary care  
 Secondary care



Last reviewed: 27-Apr-2009 Due for review: 30-Nov-2010 Printed on: 09-Nov-2009 © Map of Medicine Ltd All rights reserved

**IMPORTANT NOTE**

Last reviewed refers to the date of completion of the most recent review process for a pathway. All pathways are reviewed regularly every twelve months, and on an ad hoc basis if required.

# Bunions - surgery

<http://healthguides.mapofmedicine.com/choices/map/bunions3.html>

## 1 Bunions - surgery

### Quick info:

Severity of bunion is determined by the:

- intermetatarsal joint angle (IMA)
- metatarsophalangeal joint angle or hallux abductus angle
- severity of symptoms

## 2 Consider further investigations

### Quick info:

- radiographs are essential to plan appropriate treatment at this stage
- if not performed earlier, radiograph before surgical intervention
- consider, as necessary:
  - blood and urine analysis (to rule out infection or inflammatory disease)
  - capillary refill time
    - consider ordering vascular studies if grossly altered
  - non-invasive vascular testing
  - nerve conduction studies

## 5 Assess surgical treatment category

### Quick info:

- surgery is usually performed under general anaesthetic
- consider pre-surgery antibiotic prophylaxis

### References:

Vanore J, Christensen J, Kravitz S. Diagnosis and treatment of first metatarsophalangeal joint disorders. Section 1: Hallux valgus. J Foot Ankle Surg 2003; 42: 112-23.

Academy of Ambulatory Foot and Ankle Surgery (AAFAS). Hallux Abductovalgus. Philadelphia, PA: AAFAS; 2003.

## 6 Stage 1

### Quick info:

- in cases of hallux abductus interphalangeus, consider phalangeal osteotomy

### References:

Vanore J, Christensen J, Kravitz S. Diagnosis and treatment of first metatarsophalangeal joint disorders. Section 1: Hallux valgus. J Foot Ankle Surg 2003; 42: 112-23.

## 7 Stage 2

### Quick info:

- if there is hypermobility of the first ray or other severe deformity, consider metatarsal cuneiform arthrodesis
- if there is hallux abductus interphalangeus, consider phalangeal osteotomy
- consider excisional arthroplasty (Keller's) in:
  - older patients
  - patients with moderate deformity
  - patients with low mobility demands
- adverse effects of Keller's include:
  - cock-up deformity
  - shortening of the toe

### Reference:

Vanore J, Christensen J, Kravitz S. Diagnosis and treatment of first metatarsophalangeal joint disorders. Section 1: Hallux valgus. J Foot Ankle Surg 2003; 42: 112-23.

#### IMPORTANT NOTE

Last reviewed refers to the date of completion of the most recent review process for a pathway. All pathways are reviewed regularly every twelve months, and on an ad hoc basis if required.

# Bunions - surgery

<http://healthguides.mapofmedicine.com/choices/map/bunions3.html>

## 8 Stage 3

### Quick info:

In people with degenerative joint disease or rheumatoid arthritis, consider:

- arthrodesis (of first tarsometatarsal or of metatarsophalangeal joint)
- resection arthroplasty of first metatarsophalangeal joint, possibly with joint implant
- also consider these measures for salvage treatment where a repair operation has failed

### Reference:

Vanore J, Christensen J, Kravitz S. Diagnosis and treatment of first metatarsophalangeal joint disorders. Section 1: Hallux valgus. J Foot Ankle Surg 2003; 42: 112-23.

## 9 Soft tissue tendon balance with or without exostectomy

### Quick info:

Surgical interventions usually include:

- capsule-tendon balancing with or without surgical removal of exosis; plus
- lateral release
- capsulorrhaphy

### Reference:

Vanore J, Christensen J, Kravitz S. Diagnosis and treatment of first metatarsophalangeal joint disorders. Section 1: Hallux valgus. J Foot Ankle Surg 2003; 42: 112-23.

## 10 Soft tissue tendon balance with or without exostectomy

### Quick info:

- surgical interventions usually include:
  - capsule-tendon balancing with or without surgical removal of exosis; plus
  - lateral release
  - medial capsulorrhaphy
  - this procedure on its own may be enough to correct mild deformity

### Reference:

Vanore J, Christensen J, Kravitz S. Diagnosis and treatment of first metatarsophalangeal joint disorders. Section 1: Hallux valgus. J Foot Ankle Surg 2003; 42: 112-23.

## 11 Soft tissue tendon balance with or without exostectomy

### Quick info:

Surgical interventions usually include:

- capsule-tendon balancing with or without surgical removal of exosis; plus
- lateral release
- capsulorrhaphy

### Reference:

Vanore J, Christensen J, Kravitz S. Diagnosis and treatment of first metatarsophalangeal joint disorders. Section 1: Hallux valgus. J Foot Ankle Surg 2003; 42: 112-23.

## 12 Consider distal osteotomy

### Quick info:

- in addition to soft tissue balance with or without exostectomy, consider distal osteotomy

### References:

Vanore J, Christensen J, Kravitz S. Diagnosis and treatment of first metatarsophalangeal joint disorders. Section 1: Hallux valgus. J Foot Ankle Surg 2003; 42: 112-23.

Intracorp. Bunions. Philadelphia, PA: Intracorp; 2005.

### IMPORTANT NOTE

Last reviewed refers to the date of completion of the most recent review process for a pathway. All pathways are reviewed regularly every twelve months, and on an ad hoc basis if required.

# Bunions - surgery

<http://healthguides.mapofmedicine.com/choices/map/bunions3.html>

Ferrari J. Bunions. Clin Evid 2005; 1377-87.

Ferrari J, Higgins JP, Prior TD. Interventions for treating hallux valgus (abductovalgus) and bunions. Cochrane Database Syst Rev 2004; CD000964.

## 13 Consider osteotomy of the first metatarsal and/or proximal phalanx

Quick info:

For moderately severe bunion, consider:

- osteotomy of the proximal phalanx (Akin procedure)
- and/or one or more metatarsal osteotomies (proximal or distal)

References:

Vanore J, Christensen J, Kravitz S. Diagnosis and treatment of first metatarsophalangeal joint disorders. Section 1: Hallux valgus. J Foot Ankle Surg 2003; 42: 112-23.

Ferrari J. Bunions. Clin Evid 2005; 1377-87.

Ferrari J, Higgins JP, Prior TD. Interventions for treating hallux valgus (abductovalgus) and bunions. Cochrane Database Syst Rev 2004; CD000964.

## 14 Consider metatarsal and/or proximal phalanx osteotomy

Quick info:

For severe deformities consider:

- osteotomy of first metatarsal and/or proximal phalanx
- double osteotomy of first metatarsal
- metatarsal cuneiform arthrodesis
- phalangeal osteotomy in cases of hallux abductus interphalangeus

References:

Vanore J, Christensen J, Kravitz S. Diagnosis and treatment of first metatarsophalangeal joint disorders. Section 1: Hallux valgus. J Foot Ankle Surg 2003; 42: 112-23.

Ferrari J. Bunions. Clin Evid 2005; 1377-87.

Ferrari J, Higgins JP, Prior TD. Interventions for treating hallux valgus (abductovalgus) and bunions. Cochrane Database Syst Rev 2004; CD000964.

## 15 Special considerations for stage 1

Quick info:

In people with degenerative joint disease or rheumatoid arthritis, consider:

- arthrodesis (of first tarsometatarsal or of metatarsophalangeal joint)
- resection arthroplasty of first metatarsophalangeal joint, possibly with joint implant
- also consider these measures for salvage treatment where a repair operation has failed

Reference:

Vanore J, Christensen J, Kravitz S. Diagnosis and treatment of first metatarsophalangeal joint disorders. Section 1: Hallux valgus. J Foot Ankle Surg 2003; 42: 112-23.

## 16 Special considerations for stage 2

Quick info:

- in cases of hallux abductus interphalangeus, consider phalangeal osteotomy

References:

Vanore J, Christensen J, Kravitz S. Diagnosis and treatment of first metatarsophalangeal joint disorders. Section 1: Hallux valgus. J Foot Ankle Surg 2003; 42: 112-23.

## 17 Special considerations for stage 3

Last reviewed: 27-Apr-2009 Due for review: 30-Nov-2010 Printed on: 09-Nov-2009 © Map of Medicine Ltd All rights reserved

### IMPORTANT NOTE

Last reviewed refers to the date of completion of the most recent review process for a pathway. All pathways are reviewed regularly every twelve months, and on an ad hoc basis if required.

For terms of use please see our [Terms and Conditions](#) <http://mapofmedicine.com/map/legal>

# Bunions - surgery

<http://healthguides.mapofmedicine.com/choices/map/bunions3.html>

## Quick info:

- if there is hypermobility of the first ray or other severe deformity, consider metatarsal cuneiform arthrodesis
- if there is hallux abductus interphalangeus, consider phalangeal osteotomy
- consider excisional arthroplasty (Keller's) in:
  - older patients
  - patients with moderate deformity
  - patients with low mobility demands
- adverse effects of Keller's include:
  - cock-up deformity
  - shortening of the toe

## Reference:

Vanore J, Christensen J, Kravitz S. Diagnosis and treatment of first metatarsophalangeal joint disorders. Section 1: Hallux valgus. J Foot Ankle Surg 2003; 42: 112-23.

## 18 Follow up

### Quick info:

- immediate postoperative radiograph is useful to assess procedure
- consider regular radiographs to monitor healing at discretion of doctor and depending on type of procedure

### Reference:

Academy of Ambulatory Foot and Ankle Surgery (AAFAS). Hallux Abductovalgus. Philadelphia, PA: AAFAS; 2003.

#### IMPORTANT NOTE

Last reviewed refers to the date of completion of the most recent review process for a pathway. All pathways are reviewed regularly every twelve months, and on an ad hoc basis if required.

# Bunions - surgery

<http://healthguides.mapofmedicine.com/choices/map/bunions3.html>

## Key Dates

Due for review: 30-Nov-2010

Last reviewed: 27-Apr-2009, by International

Updated: 30-Apr-2009

## Accreditations

The editorial process used to create this pathway is accredited by:

NHS Institute for Innovation and Improvement:

Accreditation attained: 01-May-2009

Due for review: 30-Nov-2010

[Disclaimer](#)



## Certifications

The evidence for this pathway is certified by:

BMJ Publishing Group Ltd:

Certification attained: 31-Jul-2009

Due for review: 31-Jul-2010

[Disclaimer](#)



## Evidence summary for Bunions - surgery

The pathway is consistent with the following quality-appraised guidelines (6, 1, 2). All intervention nodes have been assessed for consistency with high quality guidelines and underlying evidence.

Search date: Jan-2006

## Evidence grades:

- 1** Intervention node supported by level 1 guidelines or systematic reviews
- 2** Intervention node supported by level 2 guidelines
- E** Intervention node based on expert clinical opinion
- U** Non-intervention node, not graded

## Evidence grading:

### Graded node titles that appear on this page

Consider further investigations

### Evidence grade

**U**

### Reference IDs

6, 1

Assess surgical treatment category

**2**

8, 1

Stage 2

**U**

8

Stage 3

**U**

8

Stage 1

**U**

8

Soft tissue tendon balance with or without exostectomy

**2**

8

Soft tissue tendon balance with or without exostectomy

**2**

8

Soft tissue tendon balance with or without exostectomy

**2**

8

Consider osteotomy of the first metatarsal and/or proximal phalanx

**1**

8, 4

Consider metatarsal and/or proximal phalanx osteotomy

**1**

8, 4

Consider distal osteotomy

**1**

8, 6, 4

Last reviewed: 27-Apr-2009 Due for review: 30-Nov-2010 Printed on: 09-Nov-2009 © Map of Medicine Ltd All rights reserved

### IMPORTANT NOTE

Last reviewed refers to the date of completion of the most recent review process for a pathway. All pathways are reviewed regularly every twelve months, and on an ad hoc basis if required.

For terms of use please see our [Terms and Conditions](#) <http://mapofmedicine.com/map/legal>

# Bunions - surgery

<http://healthguides.mapofmedicine.com/choices/map/bunions3.html>

Graded node titles that appear on this page	Evidence grade	Reference IDs
Special considerations for stage 2	2	8
Special considerations for stage 3	2	8
Special considerations for stage 1	2	8
Follow up	2	1

## References

This is a list of all the references that have passed critical appraisal for use in the pathway Bunions

### ID Reference

- 1 Academy of Ambulatory Foot and Ankle Surgery. Hallux abductovalgus. Philadelphia, PA: Academy of Ambulatory Foot and Ankle Surgery; 2003.  
[http://www.guideline.gov/summary/summary.aspx?ss=15&doc\\_id=4240&nbr=003240&string=hallux](http://www.guideline.gov/summary/summary.aspx?ss=15&doc_id=4240&nbr=003240&string=hallux)
- 2 Academy of Ambulatory Foot and Ankle Surgery. Metatarsalgia/intractable plantar keratosis/Tailor's bunion. Philadelphia, PA: Academy of Ambulatory Foot and Ankle Surgery; 2003.  
[http://www.guideline.gov/summary/summary.aspx?ss=15&doc\\_id=4246&nbr=003246&string=tailor's+AND+bunion](http://www.guideline.gov/summary/summary.aspx?ss=15&doc_id=4246&nbr=003246&string=tailor's+AND+bunion)
- 3 Ajis A, Koti M, Maffulli N. Tailor's bunion: a review. J Foot Ankle Surg 2005; 44: 236-245.  
[http://www.ncbi.nlm.nih.gov/sites/entrez?db=pubmed&cmd=Retrieve&dopt=AbstractPlus&list\\_uids=15940605&query\\_hl=7&itool=pubmed\\_docsum](http://www.ncbi.nlm.nih.gov/sites/entrez?db=pubmed&cmd=Retrieve&dopt=AbstractPlus&list_uids=15940605&query_hl=7&itool=pubmed_docsum)
- 4 Ferrari J, Higgins JP, Prior TD. Interventions for treating hallux valgus (abductovalgus) and bunions. Cochrane Database Syst Rev 2004; CD000964.  
[http://www.ncbi.nlm.nih.gov/sites/entrez?db=pubmed&cmd=Retrieve&dopt=AbstractPlus&list\\_uids=14973960&query\\_hl=7&itool=pubmed\\_docsum](http://www.ncbi.nlm.nih.gov/sites/entrez?db=pubmed&cmd=Retrieve&dopt=AbstractPlus&list_uids=14973960&query_hl=7&itool=pubmed_docsum)
- 5 Ferrari J. Bunions. Clin Evid 2005; 1377-1387.  
[http://www.ncbi.nlm.nih.gov/sites/entrez?db=pubmed&cmd=Retrieve&dopt=AbstractPlus&list\\_uids=16135296&query\\_hl=7&itool=pubmed\\_docsum](http://www.ncbi.nlm.nih.gov/sites/entrez?db=pubmed&cmd=Retrieve&dopt=AbstractPlus&list_uids=16135296&query_hl=7&itool=pubmed_docsum)
- 6 Intracorp. Bunions. Philadelphia, PA: Intracorp; 2005.  
[http://www.guideline.gov/summary/summary.aspx?ss=15&doc\\_id=7445&nbr=004391&string=bunions](http://www.guideline.gov/summary/summary.aspx?ss=15&doc_id=7445&nbr=004391&string=bunions)
- 7 Koti M and Maffulli N. Current concepts review: Bunionette. J Bone Joint Surg Am 2001; 83: 1076-1082.
- 8 Vanore JV, Christensen JC, Kravitz SR. Diagnosis and treatment of first metatarsophalangeal joint disorders. Section 1: Hallux valgus. J Foot Ankle Surg 2003; 42: 112-123.  
<http://www.jfas.org/article/PIIS1067251603003922/fulltext>

## Disclaimers

NHS Institute for Innovation and Improvement

It is not the function of the NHS Institute for Innovation and Improvement to substitute for the role of the clinician, but to support the clinician in enabling access to know-how and knowledge. Users of the Map of Medicine are therefore urged to use their own professional judgement to ensure that the patient receives the best possible care. Whilst reasonable efforts have been made to ensure the accuracy of the information on this online clinical knowledge resource, we cannot guarantee its correctness or completeness. The information on the Map of Medicine is subject to change and we cannot guarantee that it is up-to-date.

BMJ Publishing Group Ltd

The updates supplied by the BMJ toward the Evidence Summary are prepared by systematically reviewing certain published medical research and guidelines relevant to the topics covered, as agreed with Map of Medicine Ltd. Readers should be aware that professionals in the field may have different opinions and not all studies are covered. Because of this fact and also because of regular advances in medical research, we strongly recommend that readers independently verify any information they chose to rely on. Ultimately it is the readers' responsibility to make their own professional judgements. The BMJ Publishing Group Ltd does not independently verify the accuracy of the published research or guidelines and is not responsible for changes being made within the Map of Medicine as a result of the evidence. The updates to the Evidence Summaries are supplied on an "as is" basis without warranty of any kind express or implied and to the fullest extent permitted by law, accepts no liability for losses, injury or damage caused to any person or property (including under contract, by negligence, products liability or otherwise) whether they be direct or indirect, special, incidental or consequential, resulting from the application the information, errors or omissions in the updates supplied for Evidence Summary, the Evidence Summary, the Pathways covered by it or the research referred to in it.

Last reviewed: 27-Apr-2009 Due for review: 30-Nov-2010 Printed on: 09-Nov-2009 © Map of Medicine Ltd All rights reserved

### IMPORTANT NOTE

Last reviewed refers to the date of completion of the most recent review process for a pathway. All pathways are reviewed regularly every twelve months, and on an ad hoc basis if required.

For terms of use please see our [Terms and Conditions](http://mapofmedicine.com/map/legal) <http://mapofmedicine.com/map/legal>